

## CASE REPORT

# Case report: the role of OCT in examination of a patient with topiramate-induced acute angle closure, acute myopia and macular striae

Matías Osaba\* and Víctor Eduardo Reviglio

Instituto de la Visión Cerro, Sanatorio Allende Cerro, Córdoba, Argentina; Universidad Católica de Córdoba, Medicine, Eye Research &amp; Pathology Department, Córdoba, Argentina

\*Correspondence address. Tel:+549-351-4811-955; E-mail: doctorosaba@gmail.com

## Abstract

This work reports on a clinical case of a female who presented with headache, bilateral eye pain and vision loss. Intraocular pressures were 40 mm Hg in the right eye and 45 mm Hg in the left eye. Optical Coherence Tomography examination shows the iridocorneal angle was collapsed and macular striae were also observed. The patient had been on topiramate due to migraines 7 days before presentation. Diagnosis for topiramate-induced acute angle closure was made in both eyes. The patient showed improvement in symptoms a few days after treatment initiation and images confirmed that the iridocorneal angle had been enlarged and macular striae had disappeared.

## INTRODUCTION

Topiramate is an oral sulfonamide originally used to treat bipolar disorders and control migraine pain. The usual doses range between 50 and 400 mg daily [1]. Possible ophthalmological adverse effects include suprachoroidal effusions with forward movement of the crystalline lens and iris and subsequent narrowing of the anterior chamber, resulting in acute myopia and acute angle closure [2, 3].

## CASE REPORT

This work reports on a clinical case of a 45-year-old female who presented to us with headache, bilateral eye pain and vision loss. Visual acuity at presentation on admission was 4/10 in both eyes (20/50 Snellen scale) and did not improve with correction due to photophobia and diffuse epithelial erosions (Fig. 1).

Slit-lamp examination showed bilateral eyelid edema, chemosis, bilateral conjunctival hyperemia, surface epithelial

erosions, corneal edema, shallow anterior chamber (Van Herick 0), anterior uveitis, mid-dilated pupil and non-reactive pupils. Intraocular pressures were 40 mm Hg in the right eye and 45 mm Hg in the left eye. Fundus evaluation confirmed attached retina, optical nerve of physiological characteristics and macular striae, which were later documented with the Optical Coherence Tomography (OCT), using an “RTVUE—SD OPTOVUE” OCT (iVue® SD-OCT, Optovue, Inc., Fremont, CA). On examination the iridocorneal angle was found to be collapsed and also narrowing of the anterior chamber. The above mentioned macular striae were also observed.

The patient had been on topiramate due to migraines 7 days before presentation. A diagnosis for topiramate-induced acute angle closure was made in both eyes. First, the treatment with topiramate was immediately discontinued and ocular hypotensive medication (timolol and dorzolamide) and one tablet of acetazolamide every 12 h were administered. In addition, one eye drop of prednisolone every 2 h and one eye drop of ocular lubricant (polyacrylic acid) every 6 h were prescribed.

Received: October 18, 2017. Revised: April 10, 2018. Accepted: May 2, 2018

© The Author(s) 2018. Published by Oxford University Press.

This is an Open Access article distributed under the terms of the Creative Commons Attribution Non-Commercial License (<http://creativecommons.org/licenses/by-nc/4.0/>), which permits non-commercial re-use, distribution, and reproduction in any medium, provided the original work is properly cited. For commercial re-use, please contact [journals.permissions@oup.com](mailto:journals.permissions@oup.com)

The patient showed improvement in symptoms a few days after treatment initiation, such as recovery of visual acuity and normalization of ocular pressure. Another OCT was performed, which confirmed that the iridocorneal angle had been enlarged and the macular striae had disappeared (Fig. 2).

## DISCUSSION

Topiramate is a sulfa-derivative monosaccharide primarily used in the treatment of seizures and epilepsy in children and adults. Psychiatrists have used topiramate to treat bipolar disorders. Some publications state that the mechanisms of topiramate activity can be, on the one hand, inhibition of carbonic anhydrase and, on the other hand, potentiation of the inhibitory action of gamma-aminobutyric acid [4].

The first case reported about uveal effusion and secondary acute angle closure associated with topiramate was published by Banta *et al.* [5]. The most numerous case studies were reported by Fraunfelder in 2004 and included 115 cases of patients that underwent ocular side effects of topiramate, of which seven cases were of permanent vision loss [3]. These seven cases reporting permanent vision loss demonstrate that ignoring this potential risk of the drug can lead to serious adverse effects.

Other side effects reported include retinal vascular occlusion, visual field defects, periorbital edema, scleritis, blepharospasm, oculogyric crisis, nystagmus and diplopia [6].

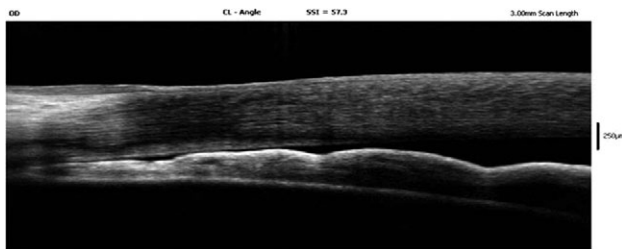


Figure 1: OCT showing closed temporal angle of right eye.

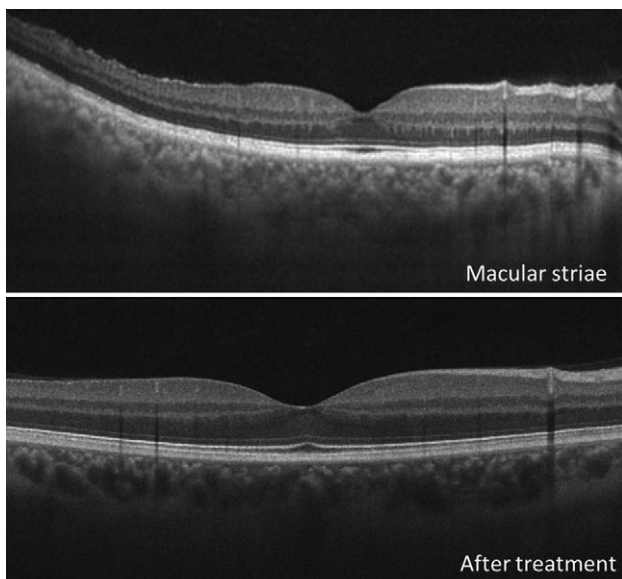


Figure 2: Macular striae of right eye during acute angle closure and after treatment.

Unlike the acute angle closure, which is rarely observed in individuals under 40 years, topiramate-induced acute angle closure has been reported in infants up to 3 years and in adults of up to 70 years, with a mean of 34 years and mainly in females (80%) [7].

The differential diagnosis of topiramate-induced acute angle closure is mainly acute angle closure or acute glaucoma. For this reason, thorough evaluation is necessary, since the treatment for conventional acute angle closure is contraindicated for topiramate-induced acute angle closure.

In some cases reported, Pilocarpine was used [8] or iridotomy was performed by using Yag Laser, which are contraindicated in topiramate-induced acute angle closure, since miotics raise intraocular pressure in the presence of uveal effusion. The indicated treatment mainly consists of discontinuing topiramate, topic (and oral ones in some cases) and mydriatic hypotensive medication, such as tropicamide.

Presentation of topiramate-induced acute angle closure usually occurs within the first 2 weeks of initiation of therapy with the drug for the first time, although some reports estimate a range of between 1 and 49 days [9]. To date there are no reports on the relationship between the dose of topiramate and the magnitude of adverse effects.

Acute myopia is one of the most common adverse effects. Myopias of up to  $-9$  diopters have been reported; this situation can occur within a few hours after starting such treatment with topiramate and can take weeks to completely disappear [10]. Acute transient myopia is a complication associated with other orally administered sulfa such as acetazolamide. According to some other studies about myopia, such complication is due to an upset of the lens osmotic balance, with a concomitant alteration of the refractive index [11].

Furthermore, the first case report on topiramate-induced acute angle closure using OCT was published in 2011 [12]. Our case report shows acute myopia, angle closure with ocular hypertension and macular striae. Development and use of techniques such as OCT have contributed to support the clinical diagnosis that helps in the clinical-pharmacological treatment.

Topiramate is an efficient antiepileptic; however, given the potential severity of ophthalmological lesions, a strict and justified use of this drug is recommended, along with the neuro-ophthalmological follow-up of these patients. It is remarkable that neurologists, or physicians, prescribing such drug, advice patients about likely visual alterations of this medicine so that the patient is able to see an ophthalmologist immediately.

## CONFLICT OF INTEREST STATEMENT

The authors declare that there is no conflict of interest regarding the publication of this article.

## FUNDING

This work did not receive any specific grant from funding agencies in the public, commercial or not-for-profit sectors.

## ETHICAL APPROVAL

Not required.

## CONSENT

The patient provided consent for the work and personal images to be published.

**GUARANTOR**

MD Osaba Matías.

**REFERENCES**

1. Natesh S, Rajashekhara SK, Rao ASD, Shetty B. Topiramate-induced angle closure with acute myopia, macular striae. *Oman J Ophthalmol* 2010;3:26–8.
2. Faught E, Wilder BJ, Ramsay RE, Reife RA, Kramer LD, Pledger GW, et al. Topiramate placebo-controlled dose-ranging trial in refractory partial epilepsy using 200-, 400-, and 600-mg daily dosages. Topiramate YD Study Group. *Neurology* 1996;46:1684–90.
3. Fraunfelder FW, Fraunfelder FT. Adverse ocular drug reactions recently identified by the National Registry of Drug-Induced Ocular Side Effects. *Ophthalmology* 2004;111:1275–9.
4. Asensio-Sánchez VM, Torreblanca-Agüera B, Martínez-Calvo S, Calvo MJ, Rodríguez R. Toxicidad oftalmológica severa por Topamax. *Arch Soc Esp Oftalmol* 2006;81:345–8.
5. Banta JT, Hoffman K, Budenz DL, Ceballos E, Greenfield DS. Presumed topiramate induced bilateral acute angle-closure glaucoma. *Am J Ophthalmol* 2001;132:112–4.
6. Dehghani A, Abtahi M-A, Abtahi S-H, Peyman A, Etemadifar M, Ghanbari H, et al. Massive bilateral choroidal detachment induced by administration of topiramate. *Case Rep Ophthalmol* 2011;2:251–5.
7. Lin J, Fosnot J, Edmond J. Bilateral angle closure glaucoma in a child receiving oral topiramate. *J AAPOS* 2003;7:66–8.
8. Sankar PS, Pasquale LR, Grosskreutz CL. Uveal effusion and secondary angle-closure glaucoma associated with topiramate use. *Arch Ophthalmol* 2001;119:1210–1.
9. Mitra A, Ramakrishnan R, Abdul Kader M. Anterior segment optical coherence tomography documentation of a case of topiramate induced acute angle closure. *Indian J Ophthalmol* 2014;62:619–22.
10. Sen HA, O'Halloran HS, Lee WB. Case reports and small case series: topiramate induced and retinal striae. *Arch Ophthalmol* 2001;119:775–7.
11. Bovino JA, Marcus DF. The mechanism of transient myopia induced by sulfonamide therapy. *Am J Ophthalmol* 1982;94:99–102.
12. van Issum C, Mavranakas N, Schutz JS, Shaarawy T. Topiramate induced acute bilateral angle closure and myopia: pathophysiology and treatment controversies. *Eur J Ophthalmol* 2011;21:404–9.