



# Juvenile osteochondritis dissecans (JOCD) of the knee: current concepts review

Javier Masquijo<sup>1</sup>  
Alpesh Kothari<sup>2</sup>

- Juvenile osteochondritis dissecans (JOCD) is a joint disorder of the subchondral bone and articular cartilage that affects skeletally immature patients.
- The aetiology of JOCD is unknown and the natural history is poorly characterized in part due to inconsistent and largely retrospective literature.
- Most OCD in children and adolescents presents as a stable lesion amenable to non-operative treatment or minimally invasive drilling. However, unstable forms can require a more aggressive approach.
- This article reviews the most recent literature available and focuses on the pathophysiology, diagnosis and treatment of JOCD of the knee.

**Keywords:** juvenile osteochondritis dissecans; knee joint; paediatric

Cite this article: *EFORT Open Rev* 2019;4:201-212.  
DOI: 10.1302/2058-5241.4.180079

## Introduction

Osteochondritis dissecans (OCD) is an acquired condition of the joint that affects the articular surface and the subchondral bone. The term osteochondritis dissecans was first coined by König in the late 1880s; he described it as an inflammation of the bone cartilage interface.<sup>1</sup> The most commonly affected joint is the knee, followed by the ankle, elbow, shoulder and hip. The juvenile form of the disease (JOCD) presents in those aged five to 16 years with open growth plates.<sup>2</sup> The causes of OCD are unknown; however, repetitive trauma, inflammation, accessory centres of ossification, ischaemia and genetic factors has been proposed.<sup>3-10</sup> The clinical presentation of JOCD is highly variable, with some children being completely asymptomatic. Pain can be poorly localized in nature; there may also be associated joint swelling and mechanical symptoms. The knee is the most common lesion site for JOCD and the most prevalent location is

within the lateral aspect of the medial femoral condyle. The goals of treatment are to promote healing of the subchondral bone and prevent chondral collapse, subsequent fracture, osteochondral defect formation and early joint degeneration. Treatment modality depends on the skeletal maturity of the patient, as well as the size, stability and location of the lesion.

The aim of this article is to provide a summary on the current literature relating to pathophysiology, diagnosis and treatment of JOCD of the knee.

## Epidemiology

The exact incidence of JOCD of the knee is unknown, with estimates in the range of 2.3/100 000 to 31.6/100 000 and is related to age, gender and race of the patient.<sup>11-13</sup> OCD seldom presents before the age of six years, most frequently presenting at 13 to 21 years.<sup>11</sup> Kessler et al demonstrated that the incidence of OCD rose from 6.8/100 000 in those aged six to 11 years to 11.2/100 000 in those aged 12 to 16 years.<sup>11</sup> Males seem to have an increased incidence of OCD than females, with male:female ratios between 2:1 and 4:1.<sup>11-13</sup> Some authors report increasing female incidence in line with increased participation levels in sports.<sup>14,15</sup> In terms of race, Kessler et al<sup>11</sup> also showed that non-Hispanic blacks had the highest incidence of OCD (31.6/100 000), with the lowest incidence observed in Asians (4.7/100 000).

JOCD of the knee most frequently occurs in the classic location of the posterolateral aspect of the medial femoral condyle.<sup>13,16-18</sup> In a large multicentre study,<sup>17</sup> 77% of lesions affected the medial femoral condyle (51% on the lateral aspect, 19% on the central aspect and 7% on the medial aspect), 17% affected the lateral femoral condyle, 7% affected the patella, 1% were trochlear lesions and only 0.2% arose from the tibial plateau.<sup>18</sup> The frequency of bilateral JOCD varies in the literature in the range of 2.7% to 30%,<sup>19-23</sup> with a typical range of 14% to 30%. There does not appear to be a preference in laterality with similar rates of right- and left-sided involvement.

## Aetiology

The precise cause of OCD is unknown, although a number of aetiological theories have been proposed. Mechanical, biological and anatomical factors may all have a role to play in the development of this disease. Greatest weight, in the literature, has been placed on mechanical factors causing OCD.<sup>24</sup> First proposed in the 1950s, the traumatic theory<sup>20</sup> has evolved from a single traumatic event to a repetitive microtrauma theory.<sup>13,25</sup> In cases involving the 'classic' OCD site at the medial femoral condyle, the repetitive microtrauma may be caused by tibial spine impingement.<sup>10,26</sup> Biomechanical factors, including obesity,<sup>4</sup> lower-limb alignment abnormalities,<sup>5</sup> soft-tissue instability<sup>27</sup> and knee activity-related positioning, have also been implicated.<sup>28</sup> Anatomic variation in the lateral femoral condyle<sup>29</sup> and posterior cruciate ligament morphology,<sup>30</sup> as well as the presence of a discoid meniscus,<sup>31</sup> may further affect the mechanical environment in the knee.

Local ischaemia has been proposed as another causative factor for OCD. Enneking demonstrated that the vascular anatomy of subchondral bone is similar to that of bowel mesentery with poor arteriole anastomoses, thereby making it susceptible to any ischaemic insult.<sup>8</sup> Abnormal vascular architecture has been demonstrated in cadaveric specimens at OCD predilection sites using novel imaging techniques.<sup>9</sup>

An increased incidence of JOCD in monozygotic twins suggests a genetic aetiology to JOCD.<sup>2,31,32</sup> In a recent study,<sup>6</sup> the proportion of patients with a positive family history of OCD was 14%. Other researchers have described familial cases of OCD lesions associated with short stature and multiple lesion sites.<sup>33</sup> Mutations in a number of candidate genes have been implicated in the development of JOCD, many of which are involved in the maintenance of turnover of cartilage.<sup>33,34</sup>

Other biological theories into the aetiology of JOCD relate to endocrine factors. Maier et al<sup>7</sup> and Bruns et al<sup>35</sup> both found a high prevalence of vitamin D deficiency in children diagnosed with JOCD presenting with significant lower mean 25-OH-D level compared with a control group. Human growth hormone deficiency can also lead to atypical ossification nuclei and the subsequent development of OCD lesions.<sup>36</sup>

Recent unpublished data from the Research in Osteochondritis of the Knee (ROCK) study group have provided new MRI findings to support previous theories regarding JOCD formation through aberrant development of only a portion of the epiphyseal growth plate.<sup>37</sup> Abnormal epiphyseal endochondral ossification may occur after a particular acute or repetitive insult, leading to a slowly evolving lesion as the patient ages. Evidence from T2 fat-saturation sequences has helped describe two potential

scenarios. The first is a permanent cessation of ossification after insult that leads to a completely cartilaginous OCD lesion without endochondral ossification. The second scenario involves temporary cessation of ossification that allows for future partial or complete normal ossification with time.<sup>37,38</sup>

With so many proposed theories, it is likely that the aetiology of OCD is multifactorial. It is the belief of the authors that OCD represents the result of repetitive microtrauma of a vulnerable osteochondral area at a vascular watershed in the genetically susceptible individual.

## Clinical manifestations

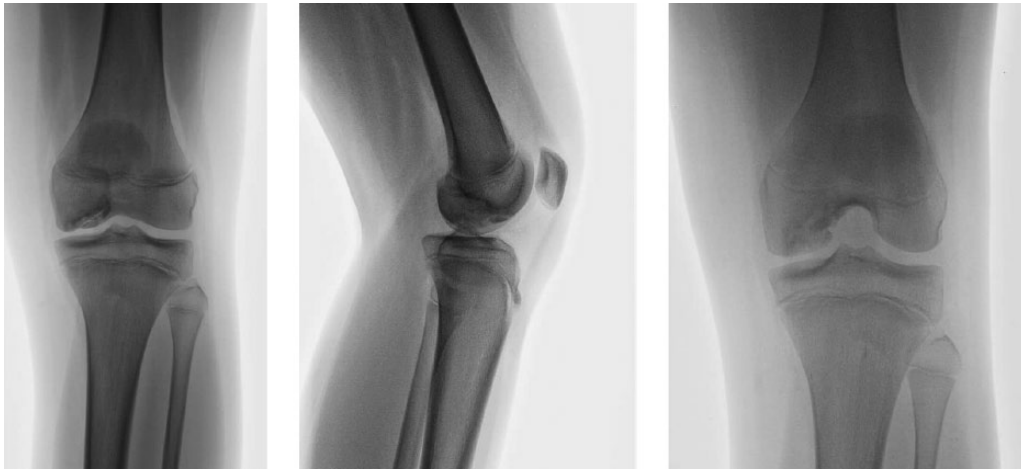The symptoms caused by JOCD are variable and will depend on the location and severity of the disease. JOCD typically presents with poorly localized, activity-related knee pain in sporty patients. Crepitus, catching or locking of the joint may occur during the later stages. The diagnosis can frequently be made by clinical findings and judicious use of imaging.

The physical examination should include careful inspection of the knee, palpation for point tenderness, assessment of joint effusion, range of motion (ROM), evaluation of limb alignment and associated injuries (ligaments/meniscus). Wilson has described a clinical test to identify the presence of JOCD of the medial femoral condyle.<sup>39</sup> It involves eliciting knee pain with internal rotation of the tibia during 30° to 90° of knee flexion and then easing the knee pain with external rotation. Unfortunately, this test has proven to be of limited diagnostic value, although it may be useful to chart the clinical progress of a patient.<sup>40,41</sup> There are no pathognomonic symptoms or signs of JOCD. A routine thorough physical examination of the hip should also be performed to rule out hip pathology, which can commonly refer pain to the knee.

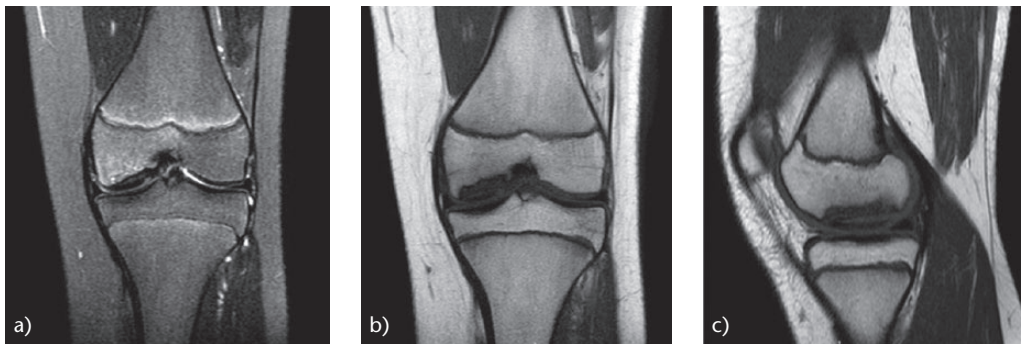
## Imaging

Anteroposterior (AP), lateral, tunnel (or notch) and sunrise radiographs are recommended in patients suspected of having JOCD (Fig. 1). Lesions located in the femoral condyle are typically more posterior and thus seen better on the tunnel view than the AP view. Characteristic findings include a well-circumscribed area of subchondral bone separated by a crescent-shaped, sclerotic and radiolucent outline of the fragment. Bilateral radiographic knee evaluation is recommended for all patients found having JOCD, as the incidence of bilateral disease is as high as 29%, of which 40% can be asymptomatic.

MRI is a valuable tool for diagnosis as well as for monitoring the progression and/or the healing of these lesions. MRI has the capability of assessing the surrounding cartilage and subchondral bone that is not seen on



**Fig. 1** AP, lateral and tunnel view radiographs of a 12-year-old girl with a lesion in the medial femoral condyle of the right knee.



**Fig. 2** MRI (of the same patient as in Figure 1). (a) T2 coronal image of the knee of an osteochondritis dissecans lesion of the medial femoral condyle; note the subchondral bone marrow oedema. (b, c) T1 coronal and sagittal images shows the presence of a large JOCD lesion that affects most of the weight-bearing area of the medial femoral condyle.

conventional radiographs and has superior detail and definition of structures within the knee joint (Fig. 2). Although MRI is the best imaging modality for JOCD with a high diagnostic sensitivity (approximately 100%), it is not possible to predict accurately the stability of the fragment.<sup>42</sup> Heywood et al<sup>43</sup> reported a specificity of 15% for diagnosing fragment instability. In a recent study from Germany,<sup>44</sup> the authors found a poor correlation between pre-operative MRI and arthroscopy morphological findings (59.6% of all patients with an OCD of the femoral condyle). Both studies agree that MRI should not be used in isolation to determine lesion stability in young patients with juvenile OCD.

### Differential diagnosis

Several conditions have clinical features that overlap with knee JOCD. Most can be identified by a careful history, physical examination and radiographs/MRI. The radiographic features of epiphyseal dysplasia can mimic the

changes of JOCD. In children aged six to eight years, normal ossification of the femoral condyles can have a misleading appearance at imaging and may resemble JOCD. Irregular, spiculated and fragmented ossification has been described and has no pathologic significance. Normal variants of ossification affect the non-weight-bearing portion of the condyles and are not associated with marrow oedema.<sup>45</sup> Torn meniscus, symptomatic discoid meniscus, osteochondral fracture, patellofemoral syndrome and symptomatic medial plicae can present similar clinical symptoms. Knee pain may also originate from a hip pathology like slipped capital femoral epiphysis (SCFE) or Legg–Calve–Perthes disease.

### Classifications

Several classification systems for OCD have been described and are based on either plain radiographs,<sup>18</sup> MRIs<sup>46</sup> and arthroscopic findings (Table 1).<sup>47</sup> No system has been universally accepted.<sup>48</sup> The Hefti classification<sup>17</sup> is commonly

**Table 1.** Proposed classification systems for osteochondritis dissecans

XR		MRI		Arthroscopy	
Berndt and Harty <sup>18</sup>		Di Paola <sup>46</sup>		Guhl <sup>47</sup>	
<b>Stage 1</b>	Small area, compression subchondral bone	Type I	Thickening of articular cartilage, but no break	Type I	Softening and irregularity of cartilage but no fragment
<b>Stage 2</b>	Partially detached OCD fragment	Type II	Breached articular cartilage, low signal rim behind fragment indicating attachment	Type II	Breached articular cartilage, with the fragment not displaceable
<b>Stage 3</b>	Fully detached OCD fragment, still in underlying crater	Type III	Breached articular cartilage, with high signal T2 changes behind fragment suggesting fluid around lesion	Type III	Definable fragment, partially attached but displaceable (flap lesion)
<b>Stage 4</b>	Complete detachment/ loose body	Type IV	Loose body and defect of articular surface	Type IV	Loose body and defect of articular surface

XR, plain radiographs; MRI, magnetic resonance imaging

used for describing MRI findings of JOCD lesions: 1) small change of signal without clear margins of fragment; 2) osteochondral fragment with clear margins but without fluid between fragment and underlying bone; 3) fluid is visible partially between fragment and underlying bone; 4) fluid is completely surrounding the fragment, but the fragment is still in situ; and 5) fragment is completely detached and displaced (loose body). The ROCK study group recently developed a novel classification system for arthroscopic evaluation of OCD of the knee that includes six arthroscopic categories: three immobile types (cue ball: no abnormality; shadow: cartilage is intact and subtly demarcated; and wrinkle in the rug: cartilage is demarcated with a fissure, buckle and/or wrinkle) and three mobile types (locked door: cartilage fissuring at periphery unable to hinge open; trapdoor: cartilage fissuring at periphery able to hinge open; and crater: exposed subchondral bone defect). This comprehensive arthroscopic classification system demonstrated excellent intra- and inter-observer reliability.<sup>49</sup>

## Treatment

Management of knee JOCD still remains a controversial topic. A recent Clinical Practice Guideline published by the American Academy of Orthopaedic Surgeons (AAOS) was unable to make any recommendations graded as ‘strong’ regarding treatment.<sup>50</sup> The best available evidence to date is limited to retrospective case series, and expert opinion, which subsequently has limited value when deciding on treatment options. Treatment decisions are influenced on clinical symptoms, skeletal maturity and characteristics of the lesion (size, location and stability).

### Conservative treatment

Conservative treatment should be the primary approach for stable JOCD of the knee. Although there is a lack of

evidence for specific non-operative treatments, most authors recommend at least three to six months before the decision for surgical treatment. Non-operative treatment options include: immobilization (casting, bracing, splinting, unloader brace); limited weight-bearing; and activity restriction. There is controversy regarding the duration and timing of these interventions. The AAOS guidelines were unable to recommend any particular non-operative treatment regimen.<sup>50</sup>

The author applies the three-phase non-operative management protocol described by Kocher et al.<sup>15</sup> The first phase involves knee immobilization for four to six weeks with crutch-protected, partial weight-bearing gait. At the end of this period, the child should be pain-free and repeat radiographs should be obtained. In phase 2 (weeks six to 12), weight-bearing as tolerated is permitted without immobilization. A rehabilitation program is initiated emphasizing knee ROM and low-impact quadriceps and hamstring strengthening exercises. Sports and repetitive-impact activities are restricted. If there are radiographic and clinical signs of healing at three to four months after the initial diagnosis, phase 3 can begin. This phase includes supervised initiation of running, jumping and cutting sports-readiness activities. A gradual return to sports with increasing intensity is allowed in the absence of knee symptoms. An MRI is repeated in phase 3 to assess healing.

Approximately 50% to 67% of JOCD lesions heal in six to 12 months with non-operative treatment and thus do not require surgery.<sup>52–56</sup> Wall et al<sup>51</sup> reported a series of patients with stable JOCD of the knee treated non-operatively. Treatment consisted of an initial six-week period of weight-bearing immobilization in a cylinder cast. If the lesion showed re-ossification on radiographs, casting was discontinued. If re-ossification was not present, the patients were allowed three to seven days out of the cast to regain ROM, followed by casting for an additional four to six weeks. After casting, patients were placed

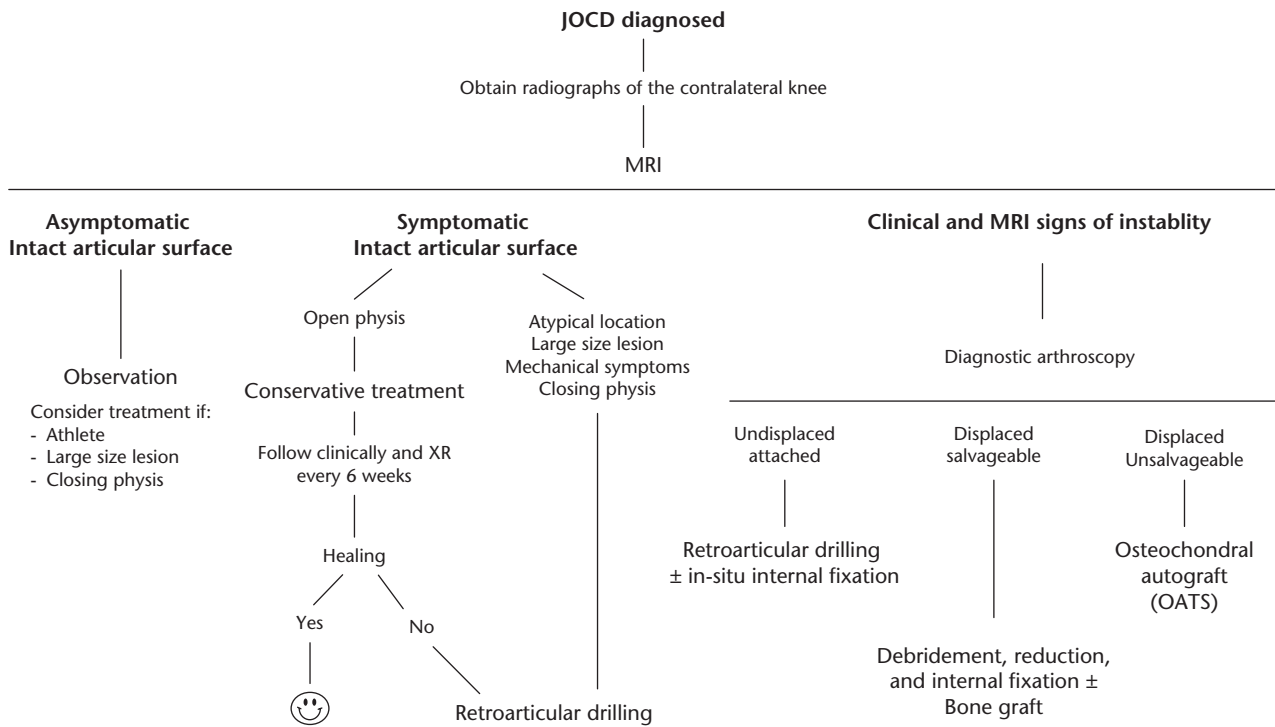


Fig. 3 Authors’ preferred treatment algorithm for JOCD of the knee.

in an unloader brace and restricted from running, jumping and sports. During this phase, patients were radiographed every six to eight weeks and activity was slowly advanced, as long as radiographs showed progression of healing. Return to full activity was allowed after complete re-ossification was demonstrated on radiographs. After six months of non-operative treatment, 31/47 lesions (66%) had progression towards healing and patients reported no pain. Samora et al<sup>55</sup> have reported that lesions in atypical locations, such as the non-weight-bearing portion of the lateral femoral condyle, are more likely to be unstable and associated with lower healing rates with non-operative treatment. Similar findings have been found for JOCD in the patellofemoral location.<sup>56</sup> Other authors have reported that presenting symptoms of effusion or mechanical features, larger lesion size, and the presence and extent of sublesional sclerosis on radiographs are predictive of non-healing at six months.<sup>51,57</sup>

Beyond a consensus that non-operative treatment should be used for at least three to six months in stable lesions, there is little agreement on which regimen is more effective. Future research in this area is required to compare different treatment protocols.

### Surgical options

Surgical treatment to promote healing is suggested in stable (immobile) lesions not responding to an initial course

of non-operative therapy and unstable (mobile) lesions. Surgery for OCD may include drilling, internal fixation and salvage procedures. The authors’ preferred treatment algorithm for OCD of the knee is based on lesion stability, skeletal maturity and clinical symptoms (Fig. 3).

### Drilling

Surgical treatment for stable lesions with intact articular cartilage involves drilling the subchondral bone. Drilling is thought to disrupt the sclerotic margin of the lesion and consequently promote healing via growth factors released from healthy underlying cancellous bone. Arthroscopically confirmed stable JOCD lesions can be drilled either in a transarticular or retroarticular fashion. The authors’ preferred technique is retroarticular drilling with fluoroscopic guidance.<sup>58</sup> This technique spares the articular surface and physes by drilling through the affected condyle. Retroarticular drilling and bone grafting using a bone marrow biopsy needle has also been described.<sup>59,60</sup> On the other hand, transarticular drilling penetrates the lesion through the articular cartilage. Concerns with this technique involve the uncertain long-term implications for joint surface damage created by articular cartilage drill sites. Also, from a practical standpoint, far posterior condylar lesions may be difficult to access from a transarticular approach.



## Pre-operative planning

The primary limitation of retroarticular drilling is the requirement for fluoroscopy and its associated radiation. Intra-operative fluoroscopy can be a challenge because the superimposed radiographic density of the musculo-skeletal structures may obscure visualization of the lesion in the lateral view. Consequently, most surgeries require multiple shots for the identification of the lesion and K-wire placement. The author described a new pre-operative position assessment system that can therefore allow surgeons to more accurately identify the JOCD lesion during retroarticular drilling using radiographic landmarks (Fig. 4).<sup>61</sup> This technique may help avoid excessive intra-operative radiation and expedite intervention.

## Surgical technique

Surgery is performed under general or spinal anaesthesia using a thigh tourniquet. Diagnostic arthroscopy is performed to confirm intact articular cartilage. The arthroscopy equipment is then removed from the joint and the C-arm is positioned. AP, tunnel and true lateral views are obtained, identifying the area of the JOCD lesion. Under fluoroscopic guidance, a 1.6-mm K-wire is inserted percutaneously using free-hand technique at a level below the physis toward the centre of the lesion just beneath the articular cartilage in a retrograde fashion. Multiple parallel K-wires are placed into different positions within the lesion using the first K-wire as a guide (Fig. 4). It is important to check the direction of the guide wire under AP, tunnel and lateral fluoroscopic views to reach the lesion accurately. After drilling, the tourniquet is released, the arthroscopic portals are closed with subcuticular sutures and a dressing is then applied.

Patients immediately begin a series of active motion exercises of the knee after surgery. Physical therapy is performed from the second week after surgery. Full weight-bearing is permitted six weeks post-operatively and sporting activities after four to six months. Return to play is allowed once the lesion has healed and quadriceps strength has returned to within normal limits.

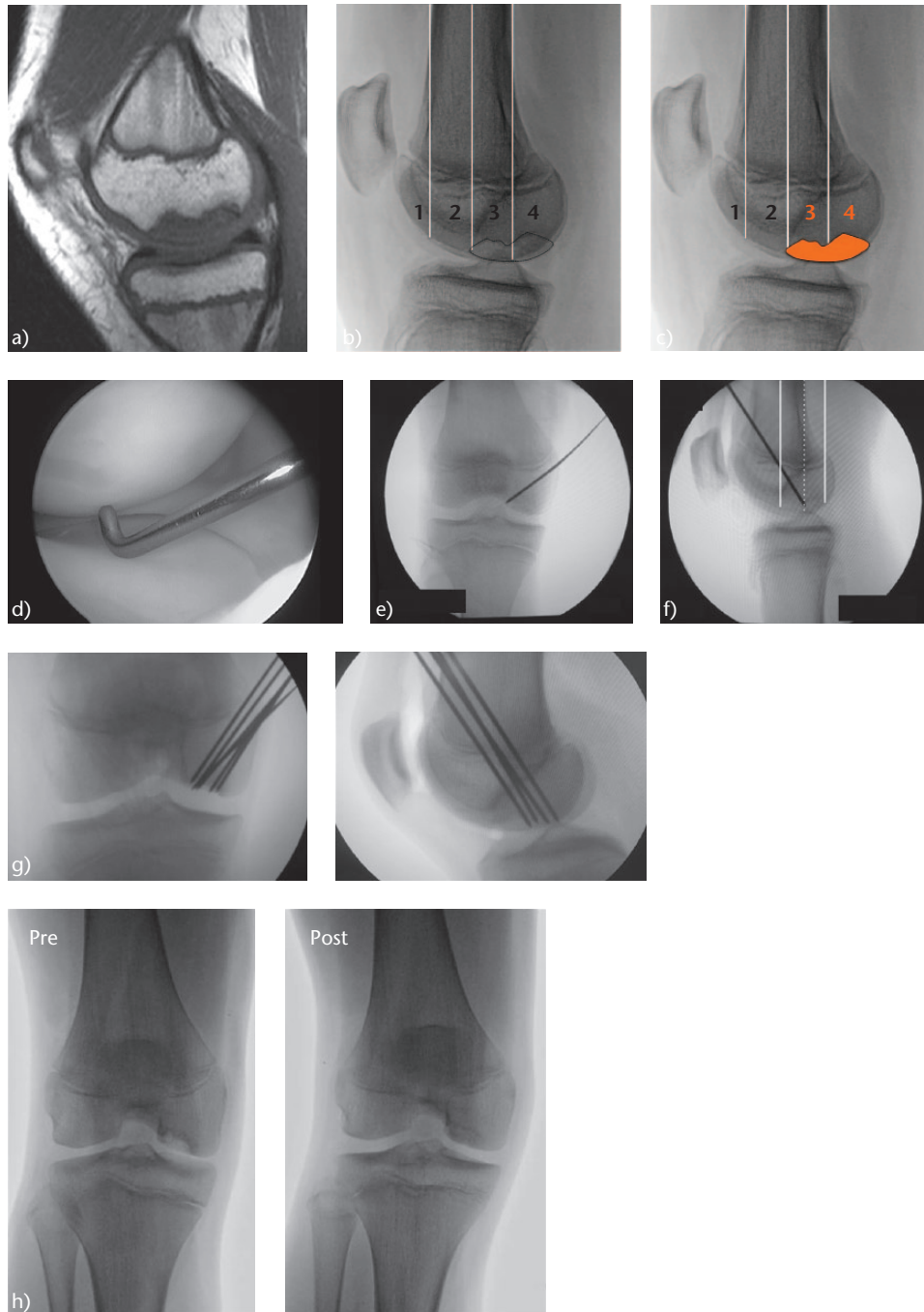
## Outcomes

Outcomes of OCD drilling are favourable in most cases (Table 2). High rates of healing with low complication rates have been reported using either transarticular or retroarticular drilling modalities. Gunton et al<sup>78</sup> systematically reviewed the short-term clinical outcomes of retroarticular and transarticular drilling of stable OCD lesions. Twelve studies met inclusion criteria, 111 lesions were treated with retroarticular drilling and 94 were treated with transarticular drilling. Both techniques

resulted in comparable radiographic healing at 86% and 91%, respectively, occurring at a mean of four to six months, with no reported complications.

## Internal fixation

If there is any doubt about stability, internal fixation is necessary in addition to drilling. If accessible (trapdoor lesions), the fibrous tissue from base of the lesion and bony surface of the flap are debrided with a curette or arthroscopic shaver. If there is a resultant bone void, bone grafting from the proximal tibia or iliac crest is performed. Fixation can be accomplished with multiple metal or bioabsorbable devices.<sup>79–83</sup> Cannulated screws, Herbert screws, bone pegs and metal staples have been used. Disadvantages with metallic implants include MRI interference and the requirement of a second surgery to remove many of these devices. Metallic implants have been associated with many complications such as migration, breakage and loosening.<sup>47</sup> These concerns have led to the development of bioabsorbable implants. Bioabsorbable devices have been made from polyglycolic acid (PGA) or polylactic acid (PLA). PGA has a rapid degradation rate, reportedly absorbing in three months with high incidence of foreign body reactions.<sup>84</sup> PLA, which was later introduced in response to problems encountered with PGA devices, can take as long as six years to absorb and may place opposing cartilage at risk for damage by the implant.<sup>85,86</sup> Most recent devices comprised both PGA and PLA copolymer with the aim of maximizing their beneficial effects while minimizing the inflammatory reaction elicited from degradation products.<sup>87</sup> In most cases, fixation is accomplished with two to four of these implants, to impart compression and rotational stability to the fragment; the lengths are chosen pre-operatively to avoid violating the growth plate (usually 20 or 25 mm in length). Tabaddor et al<sup>87</sup> reported the outcomes of 24 patients (24 knees) with unstable OCD lesions of the knee that were treated with Smart Nails® (ConMed Linvatec Ltd., Tampere, Finland). The mean age at the time of surgery was 14.4 years. The mean follow-up was 39.6 months. Plain films at an average of 19.2 months post-operatively revealed interval healing in nine patients, no significant change in one patient, complete healing in 13 patients and loose bodies with no interval healing in one patient. Of the 24 patients, 22 (91.7%) had good-to-excellent outcomes. Two of the 24 patients experienced complications and their OCD lesions did not heal clinically/radiographically, requiring re-operation for further fixation. More recently, a study from Japan reported improved clinical outcomes and 97% radiographic healing rate at a mean of 3.3 years of follow-up.<sup>88</sup>



**Fig. 4** Retroarticular drilling. Pre-operative planning. (a) Using a T1 sagittal sequence, the lesion is identified in its maximum extension. (b) This image is transferred to the lateral radiograph – three lines are marked: (1) anterior cortex, (2) mid-diaphyseal, and (3) posterior cortex. Then four zones are delimited. (c) The extension of the lesion in the zones and its most central point that corresponds to the first placed K-wire is determined (in this case between zones 3 and 4, with its midpoint between both). Intra-operative. (d) Arthroscopic confirmation of the stability of the lesion. (e) Under fluoroscopic guidance, a 1.6-mm K-wire is placed percutaneously using free-hand technique at a level below the physis, and directed obliquely, down through the femoral condyle in a retrograde fashion. (f) Accurate placement of the central K-wire is checked under fluoroscopic view. (g) Ten to 12 perforations are made around the central K-wire. (h) Pre-operative and six months post-operative tunnel view radiograph showing complete healing.

**Table 2. Outcomes with transarticular and retroarticular drilling**

Study	Year	LOE	Drilling technique	n	Follow-up (months)*	Age at time of surgery (years)*	Complications	Healing†	Time to healing on radiographs (months)*
Lee and Mercurio <sup>65</sup>	1981	IV	Retroarticular	1	7 (6–7)	18 (12–26)	None	100% (1/1)	NR
Bradley and Dandy <sup>66</sup>	1989	IV	Transarticular	11	24 (12–60)	12 (11–13)	NR	91% (10/11)	NR
Aglietti et al <sup>67</sup>	1994	IV	Transarticular	16	56 (34–104)	12.8 (10–14)	None	100% (16/16)	4.9 (2–8)
Anderson et al <sup>68</sup>	1997	IV	Transarticular	20	60 (24–108)	13.5 (9–23)	None	90% (18/20)	4.4 (1–9)
Kocher et al <sup>69</sup>	2001	IV	Transarticular	30	45 (24–86)	12.3 (8.5–16.1)	NR	100% (30/30)	4.4 (1–11)
Louisia et al <sup>70</sup>	2003	IV	Transarticular	17	141 (36–312)	13.8 (11–29)	NR	70.6% (12/17)	NR
Kawasaki et al <sup>71</sup>	2003	IV	Retroarticular	15	16 (12–24)	12.5 (9–18)	NR	100% (15/15)	4 (3–5)
Donaldson and Wojtys <sup>72</sup>	2008	IV	Retroarticular	16	21 (8–38)	12.3 (9–15)	None	100% (16/16)	8.5 (5–14.5)
Baroni and Masquijo <sup>61</sup>	2009	IV	Retroarticular	21	68 (12–216)	12.1 (10–17)	None	90.5% (19/21)	3.4 (NR)
Adachi et al <sup>73</sup>	2009	IV	Retroarticular	20	32 (13–62)	12 (9–15)	None	95% (19/20)	4.4 (2–8)
Edmonds et al <sup>74</sup>	2010	IV	Retroarticular	59	36.3 (1.3–72)	13.4 (8–18.6)	None	83% (49/59)	11.8 (1.3–47.3)
Hayan et al <sup>75</sup>	2010	IV	Transarticular	40	14.8 (NR)	13.4 (NR)	None	95% (38/40)	NR
Goebel et al <sup>76</sup>	2011	IV	Retroarticular	35	37.9 (NR)	NR	NR	88.2% (NR)	NR
Ojala et al <sup>77</sup>	2011	IV	Retroarticular	5	36.6 (4–79)	15 (7–21)	None	80% (8/10)	NR
Boughanem et al <sup>78</sup>	2011	IV	Retroarticular	31	48 (18–84)	12.7 (8–16)	None	97% (33/34)	NR
Yonetani et al <sup>79</sup>	2012	IV	Transarticular	18	30 (24–48)	12 (11–14)	NR	79% (15/19)	NR
Shaikh et al <sup>80</sup>	2015	IV	Transarticular	17	26 (NR)	13.2 (NR)	None	76% (13/17)	NR

\*Values are expressed as means with ranges in parentheses

†Values are expressed as percentages with total numbers in parentheses

LOE, level of evidence; NR, not reported

Autogenous osteochondral plugs have recently been presented as a biologic alternative to the use of hardware. The plugs provide bone graft as well as fixation of the lesion. Three studies<sup>89–91</sup> reported that biological fixation provided healing of the osteochondral fragment with promising results.

More recently, hybrid fixation has been proposed as an alternative method. Hybrid fixation allows preservation of the osteochondral fragment with unstable femoral condyle OCD, by combining mechanical (screws) and biological (osteochondral autograft transplantation surgery (OATS)) fixation. Lintz et al<sup>92</sup> and Chadli et al<sup>93</sup> obtained good or excellent outcomes with this technique.

### Salvage techniques

When the progeny fragment has comminuted into multiple small fragments or is incongruous with the donor site, or the articular cartilage is excessively deteriorated, primary fixation may not be the most viable option.<sup>94</sup> There are several salvage techniques for full-thickness defects, such as marrow stimulation (microfractures), OATS, fresh osteochondral allograft, autologous chondrocyte implantation (ACI) and matrix-induced autologous chondrocyte implantation (MACI). This is a very unusual scenario for the paediatric–adolescent population and literature is scarce on clinical outcome data.

Marrow stimulation techniques such as microfracture involve breaching the subchondral bone to allow the influx of pluripotent stem cells from the marrow into the osteochondral defect, resulting in fibrocartilage formation.<sup>95</sup> Microfracture is indicated in patients with a localized small cartilage defect. However, in most OCD lesions

this may not be possible as the subchondral bone is often absent. The OATS technique transfers both articular cartilage and subchondral bone from a non-weight-bearing area of the knee to the site of the defect and is most effective in lesions < 2.5 cm<sup>2</sup>.<sup>96</sup> Gudas et al<sup>97</sup> randomized 50 children with a mean age of 14.3 years (12 to 18) to either microfracture or OATS for treatment of femoral condylar JOCD. At one year, both groups had good or excellent results in their functional and objective assessment, but at 4.2 years, the OATS group maintained an 83% good or excellent result, while the microfracture group dropped to 63%. Failure rates were 41% in the microfracture group and 0% in the OATS group, with an inverse relationship between defect size and outcome in the microfracture group, without a similar relationship in the OATS group. Only 14% of patients in the microfracture group returned to their preinjury level at 4.2 years *versus* 81% in the OATS group.

For larger lesions, osteochondral allograft transplantation procedures may be used. Advantages of this approach include the avoidance of donor-site morbidity and the ability to address large lesions with a single operation, concerns over the phenomenon of creep substitution and long-term maintenance of graft incorporation make additional follow-up studies critical to more widespread adoption of the procedure.<sup>98</sup>

ACI is a two-stage cellularly based autograft technique.<sup>99</sup> The first stage involves an arthroscopic biopsy from healthy cartilage in the non-weight-bearing region of the intercondylar notch. These cells are grown in vitro over four to six weeks, at which point the patient returns for implantation. During this procedure, the calcified cartilage is removed and the lesion is debrided to stable vertical



walls. The defect is covered with a periosteal patch from the proximal tibia or a synthetic collagen membrane that is sutured using interrupted 5-0 or 6-0 Vicryl sutures to the healthy edges of the debrided defect. Fibrin glue is then used to seal the edges and the cultured cells are injected beneath the patch. One edge is left open until the cells are injected. The remaining defect is then securely closed with sutures and glue. Several clinical studies have reported promising results. Mithofer et al<sup>100</sup> reported 96% good to excellent outcomes at the mid-term in adolescent patients undergoing ACI for OCD. Similarly, 96% of patients also returned to high-impact sports and 60% returned to a level equal or higher than before their knee injury. Improved results were seen in patients with shorter duration of symptoms (< 12 months) and fewer surgeries. A recent systematic review of ACI on 115 adolescents (five studies) who underwent ACI showed an average improvement of outcome scores near 40%. Mean patient age was 16.2 years (11 to 21). Mean follow-up was 52.3 months (12 to 74). Mean defect size was 5.3 cm<sup>2</sup> (0.96 to 14). Graft hypertrophy was the most common complication (7%).<sup>101</sup>

### Future directions: the role of the ROCK study group

The ROCK study group was founded in 2010 to improve the outcomes of patients with knee OCD through multicentre research. The ongoing work of the ROCK study group includes development of a detailed and validated MRI classification system, a multicentre randomized trial of transarticular *versus* retroarticular drilling of stable OCDs in skeletally immature patients, and a multicentre prospective cohort of conservative and surgical treatment of knee OCD.<sup>102</sup>

### Conclusions

The diagnosis of JOCD of the knee should be considered in young, active patients who have knee pain. Early diagnosis and treatment are essential to prevent cartilage destruction and preserve joint function. Treatment should be individualized, based on the patient's skeletal maturity, as well as the size, stability and location of the lesion. Although there is limited high-quality literature surrounding the optimal management and prognosis of JOCD of the knee, paediatric orthopaedic surgeons can draw upon current best practices outlined by the AAOS and ROCK organizations.<sup>50</sup> Conservative treatment should be the first-line treatment for stable (immobile) lesions. Surgical treatment for stable lesions with intact articular cartilage involves drilling the subchondral bone aiming to stimulate vascular ingrowth and subchondral bone healing. If the lesion is unstable (mobile), fixation is indicated. Every attempt should be

made to retain the osteochondral fragment when possible. If fixation is not possible, there are multiple salvage techniques but with limited outcome data in this patient population. Future multicentre research on this condition should focus on optimizing non-operative and surgical treatment utilizing youth-validated patient-reported outcomes to determine optimum treatment protocols.

#### AUTHOR INFORMATION

<sup>1</sup>Department of Pediatric Orthopaedics, Sanatorio Allende, Córdoba, Argentina.

<sup>2</sup>Department of Paediatric Orthopaedics, Oxford University Hospitals NHS Foundation Trust, Oxford, UK.

Correspondence should be sent to: Javier Masquijo, Department of Pediatric Orthopaedics, Sanatorio Allende, H. Irigoyen 384, Nueva Córdoba. CP5009, Córdoba, Argentina.

Email: jmasquijo@gmail.com

#### ICMJE CONFLICT OF INTEREST STATEMENT

The authors declare no conflict of interest relevant to this work.

#### FUNDING STATEMENT

No benefits in any form have been received or will be received from a commercial party related directly or indirectly to the subject of this article.

#### LICENCE

© 2019 The author(s)

This article is distributed under the terms of the Creative Commons Attribution-Non Commercial 4.0 International (CC BY-NC 4.0) licence (<https://creativecommons.org/licenses/by-nc/4.0/>) which permits non-commercial use, reproduction and distribution of the work without further permission provided the original work is attributed.

#### REFERENCES

- König F.** Über freie Körper in den gelenken. *Deutsche Zeitschrift für Chirurgie* 1888;27(1–2):90–109. in German. doi:10.1007/BF02792135
- De Smet AA, Ilahi OA, Graf BK.** Untreated osteochondritis dissecans of the femoral condyles: prediction of patient outcome using radiographic and MR findings. *Skeletal Radiol* 1997;26(8):463–467. doi:10.1007/s002560050267
- Gans I, Sarkissian EJ, Grant SF, Ganley TJ.** Identical osteochondritis dissecans lesions of the knee in sets of monozygotic twins. *Orthopedics* 2013;36(12):e1559–e1562. doi:10.3928/01477447-20131120-23
- Kessler JI, Jacobs JC Jr, Cannamela PC, Shea KG, Weiss JM.** Childhood obesity is associated with osteochondritis dissecans of the knee, ankle, and elbow in children and adolescents. *J Pediatr Orthop* 2018;38(5):e296–e299. doi:10.1097/BPO.0000000000001158
- Gonzalez-Herranz P, Rodriguez ML, de la Fuente C.** Femoral osteochondritis of the knee: prognostic value of the mechanical axis. *J Child Orthop* 2017;11(1):1–5. doi:10.1302/1863-2548-11-160173
- Gornitzky AL, Mistovich RJ, Atuahene B, Storey EP, Ganley TJ.** Osteochondritis dissecans lesions in family members: does a positive family history impact

phenotypic potency? *Clin Orthop Relat Res* 2017;475(6):1573–1580. doi:10.1007/s11999-016-5059-x

**7. Maier GS, Lazovic D, Maus U, et al.** Vitamin D deficiency: the missing etiological factor in the development of juvenile osteochondritis dissecans? *J Pediatr Orthop* 2019;39:51–54. doi:10.1097/BPO.0000000000000921

**8. Enneking WF.** *Clinical Musculoskeletal Pathology*. 3rd ed. Gainesville, FL: University of Florida Press, 1990:166.

**9. Tóth F, Nissi MJ, Ellermann JM, et al.** Novel application of magnetic resonance imaging demonstrates characteristic differences in vasculature at predilection sites of osteochondritis dissecans. *Am J Sports Med* 2015;43(10):2522–2527. doi:10.1177/0363546515596410

**10. Cavaignac E, Perroncel G, Thépaut M, et al.** Relationship between tibial spine size and the occurrence of osteochondritis dissecans: an argument in favour of the impingement theory. *Knee Surg Sports Traumatol Arthrosc* 2017;25(8):2442–2446. doi:10.1007/s00167-015-3907-y

**11. Kessler JI, Nikizad H, Shea KG, et al.** The demographics and epidemiology of osteochondritis dissecans of the knee in children and adolescents. *Am J Sports Med* 2014;42(2):320–326. doi:10.1177/0363546513510390

**12. Schenck RC Jr, Goodnight JM.** Osteochondritis dissecans. *J Bone Joint Surg Am* 1996;78(3):439–456. doi:10.2106/00004623-199603000-00018

**13. Lindén B.** The incidence of osteochondritis dissecans in the condyles of the femur. *Acta Orthop Scand* 1976;47(6):664–667. doi:10.3109/17453677608988756

**14. Cahill BR.** Osteochondritis dissecans of the knee: treatment of juvenile and adult forms. *J Am Acad Orthop Surg* 1995;3(4):237–247. doi:10.5435/00124635-199507000-00006

**15. Kocher MS, Tucker R, Ganley TJ, Flynn JM.** Management of osteochondritis dissecans of the knee: current concepts review. *Am J Sports Med* 2006;34(7):1181–1191. doi:10.1177/0363546506290127

**16. Aichroth P.** Osteochondritis dissecans of the knee. A clinical survey. *J Bone Joint Surg [Br]* 1971;53-B(3):440–447. doi:10.1302/0301-620X.53B3.440

**17. Hefti F, Beguiristain J, Krauspe R, et al.** Osteochondritis dissecans: a multicenter study of the European Pediatric Orthopedic Society. *J Pediatr Orthop B* 1999;8(4):231–245.

**18. Berndt AL, Harty M.** Transchondral fractures (osteochondritis dissecans) of the talus. *J Bone Joint Surg [Am]* 1959;41-A(6):988–1020. doi:10.2106/00004623-195941060-00002

**19. Marsden C, Wiernik G.** The incidence of osteochondritis dissecans. *J R Army Med Corps* 1956;102(2):124–130.

**20. Green WT, Banks HH.** Osteochondritis dissecans in children. *J Bone Joint Surg [Am]* 1953;35-A(1):26–47, passim. doi:10.2106/00004623-195335010-00004

**21. Mubarak SJ, Carroll NC.** Juvenile osteochondritis dissecans of the knee: etiology. *Clin Orthop Relat Res* 1981;(157):200–211. doi:10.1097/00003086-198106000-00033

**22. Hughston JC, Hergenroeder PT, Courtenay BG.** Osteochondritis dissecans of the femoral condyles. *J Bone Joint Surg [Am]* 1984;66-A(9):1340–1348. doi:10.2106/00004623-198466090-00003

**23. Cooper T, Boyles A, Samora WP, Klingele KE.** Prevalence of bilateral JOCD of the knee and associated risk factors. *J Pediatr Orthop* 2015;35(5):507–510. doi:10.1097/BPO.0000000000000323

**24. Andriolo L, Crawford DC, Reale D, et al.** Osteochondritis dissecans of the knee: etiology and pathogenetic mechanisms. A systematic review. *Cartilage* 2018. Epub ahead of print. doi:10.1177/1947603518786557

**25. Uozumi H, Sugita T, Aizawa T, et al.** Histologic findings and possible causes of osteochondritis dissecans of the knee. *Am J Sports Med* 2009;37(10):2003–2008. doi:10.1177/0363546509346542

**26. Chow RM, Guzman MS, Dao Q.** Intercondylar notch width as a risk factor for medial femoral condyle osteochondritis dissecans in skeletally immature patients. *J Pediatr Orthop* 2016;36(6):640–644. doi:10.1097/BPO.0000000000000511

**27. Deroussen F, Hustin C, Moukoko D, Collet LM, Gouron R.** Osteochondritis dissecans of the lateral tibial condyle associated with agenesis of both cruciate ligaments. *Orthopedics* 2014;37(2):e218–e220. doi:10.3928/01477447-20140124-30

**28. McElroy MJ, Riley PM, Tepolt FA, Nasreddine AY, Kocher MS.** Catcher's knee: posterior femoral condyle juvenile osteochondritis dissecans in children and adolescents. *J Pediatr Orthop* 2018;38(8):410–417. doi:10.1097/BPO.0000000000000839

**29. Kamei G, Adachi N, Deie M, et al.** Characteristic shape of the lateral femoral condyle in patients with osteochondritis dissecans accompanied by a discoid lateral meniscus. *J Orthop Sci* 2012;17(2):124–128. doi:10.1007/s00776-011-0190-8

**30. Ishikawa M, Adachi N, Yoshikawa M, et al.** Unique anatomic feature of the posterior cruciate ligament in knees associated with osteochondritis dissecans. *Orthop J Sports Med* 2016;4(5):2325967116648138. doi:10.1177/2325967116648138

**31. Takigami J, Hashimoto Y, Tomihara T, et al.** Predictive factors for osteochondritis dissecans of the lateral femoral condyle concurrent with a discoid lateral meniscus. *Knee Surg Sports Traumatol Arthrosc* 2018;26(3):799–805. doi:10.1007/s00167-017-4451-8

**32. Richie LB, Sytsma MJ.** Matching osteochondritis dissecans lesions in identical twin brothers. *Orthopedics* 2013;36(9):e1213–e1216. doi:10.3928/01477447-20130821-27

**33. Stattin EL, Tegner Y, Domellöf M, Dahl N.** Familial osteochondritis dissecans associated with early osteoarthritis and disproportionate short stature. *Osteoarthritis Cartilage* 2008;16(8):890–896. doi:10.1016/j.joca.2007.11.009

**34. Jackson GC, Marcus-Soekarman D, Stolte-Dijkstra I, et al.** Type IX collagen gene mutations can result in multiple epiphyseal dysplasia that is associated with osteochondritis dissecans and a mild myopathy. *Am J Med Genet A* 2010;152A(4):863–869. doi:10.1002/ajmg.a.33240

**35. Bruns J, Werner M, Soyka M.** Is vitamin D insufficiency or deficiency related to the development of osteochondritis dissecans? *Knee Surg Sports Traumatol Arthrosc* 2016;24(5):1575–1579. doi:10.1007/s00167-014-3413-7

**36. Hussain WM, Hussain HM, Hussain MS, Ho SS.** Human growth hormone and the development of osteochondritis dissecans lesions. *Knee Surg Sports Traumatol Arthrosc* 2011;19(12):2108–2110. doi:10.1007/s00167-010-1370-3

**37. Edmonds EW, Polousky J.** A review of knowledge in osteochondritis dissecans: 123 years of minimal evolution from König to the ROCK study group. *Clin Orthop Relat Res* 2013;471(4):1118–1126. doi:10.1007/s11999-012-2290-y

**38. D'Angelo K, Kim P, Murnaghan ML.** Juvenile osteochondritis dissecans in a 13-year-old male athlete: a case report. *J Can Chiropr Assoc* 2014;58(4):384–394.

**39. Wilson JN.** A diagnostic sign in osteochondritis dissecans of the knee. *J Bone Joint Surg [Am]* 1967;49-A(3):477–480. doi:10.2106/00004623-196749030-00006

**40. Conrad JM, Stanitski CL.** Osteochondritis dissecans: Wilson's sign revisited. *Am J Sports Med* 2003;31(5):777–778. doi:10.1177/03635465030310052301

**41. Zaremski JL, Herman DC, Vincent KR.** Clinical utility of Wilson test for osteochondral lesions at the knee. *Curr Sports Med Rep* 2015;14(6):430. doi:10.1249/JSR.0000000000000203

- 42. Quatman CE, Quatman-Yates CC, Schmitt LC, Paterno MV.** The clinical utility and diagnostic performance of MRI for identification and classification of knee osteochondritis dissecans. *J Bone Joint Surg [Am]* 2012;94(11):1036–1044. doi:10.2106/JBJS.K.00275
- 43. Heywood CS, Benke MT, Brindle K, Fine KM.** Correlation of magnetic resonance imaging to arthroscopic findings of stability in juvenile osteochondritis dissecans. *Arthroscopy* 2011;27(2):194–199. doi:10.1016/j.arthro.2010.07.009
- 44. Roßbach BP, Paulus AC, Niethammer TR, et al.** Discrepancy between morphological findings in juvenile osteochondritis dissecans (OCD): a comparison of magnetic resonance imaging (MRI) and arthroscopy. *Knee Surg Sports Traumatol Arthrosc* 2016;24(4):1259–1264. doi:10.1007/s00167-015-3724-3
- 45. Jans LB, Jaremko JL, Ditchfield M, Verstraete KL.** Evolution of femoral condylar ossification at MR imaging: frequency and patient age distribution. *Radiology* 2011;258(3):880–888. doi:10.1148/radiol.10101103
- 46. Dipaola JD, Nelson DW, Colville MR.** Characterizing osteochondral lesions by magnetic resonance imaging. *Arthroscopy* 1991;7(1):101–104. doi:10.1016/0749-8063(91)90087-E
- 47. Guhl JF.** Arthroscopic treatment of osteochondritis dissecans. *Clin Orthop Relat Res* 1982;(167):65–74.
- 48. Jacobs JC Jr, Archibald-Seiffer N, Grimm NL, Carey JL, Shea KG.** A review of arthroscopic classification systems for osteochondritis dissecans of the knee. *Orthop Clin North Am* 2015;46(1):133–139. doi:10.1016/j.ocl.2014.09.009
- 49. Carey JL, Wall EJ, Grimm NL, et al; Research in Osteochondritis of the Knee (ROCK) Group.** Novel arthroscopic classification of osteochondritis dissecans of the knee: a multicenter reliability study. *Am J Sports Med* 2016;44(7):1694–1698. doi:10.1177/0363546516637175
- 50. American Academy of Orthopedic Surgeons.** *Clinical practice guideline on the diagnosis and treatment of osteochondritis dissecans.* Rosemont, IL: American Academy of Orthopedic Surgeons, 2010. [http://www.aaos.org/research/guidelines/OCD\\_guideline.pdf](http://www.aaos.org/research/guidelines/OCD_guideline.pdf).
- 51. Wall EJ, Vourazeris J, Myer GD, et al.** The healing potential of stable juvenile osteochondritis dissecans knee lesions. *J Bone Joint Surg [Am]* 2008;90(12):2655–2664. doi:10.2106/JBJS.G.01103
- 52. Krause M, Hapfelmeier A, Möller M, et al.** Healing predictors of stable juvenile osteochondritis dissecans knee lesions after 6 and 12 months of nonoperative treatment. *Am J Sports Med* 2013;41(10):2384–2391. doi:10.1177/0363546513496049
- 53. Pill SG, Ganley TJ, Milam RA, et al.** Role of magnetic resonance imaging and clinical criteria in predicting successful nonoperative treatment of osteochondritis dissecans in children. *J Pediatr Orthop* 2003;23(1):102–108. doi:10.1097/01241398-200301000-00021
- 54. Cahill BR, Phillips MR, Navarro R.** The results of conservative management of juvenile osteochondritis dissecans using joint scintigraphy. A prospective study. *Am J Sports Med* 1989;17(5):601–605. doi:10.1177/036354658901700502
- 55. Samora WP, Chevillet J, Adler B, Young GS, Klingele KE.** Juvenile osteochondritis dissecans of the knee: predictors of lesion stability. *J Pediatr Orthop* 2012;32(1):1–4. doi:10.1097/BPO.0b013e31823d8312
- 56. Wall EJ, Heyworth BE, Shea KG, et al.** Trochlear groove osteochondritis dissecans of the knee patellofemoral joint. *J Pediatr Orthop* 2014;34(6):625–630. doi:10.1097/BPO.0000000000000212
- 57. Ramirez A, Abril JC, Chaparro M.** Juvenile osteochondritis dissecans of the knee: perifocal sclerotic rim as a prognostic factor of healing. *J Pediatr Orthop* 2010;30(2):180–185. doi:10.1097/BPO.0b013e3181cfd2e
- 58. Baroni E, Lambert N, Masquijo JJ.** Osteochondritis Dissecans Juvenil de Rodilla: Tratamiento Artroscópico con Perforaciones Extraarticulares. *Arthroscopia* 2009;16(2):129–134.
- 59. Lebolt JR, Wall EJ.** Retroarticular drilling and bone grafting of juvenile osteochondritis dissecans of the knee. *Arthroscopy* 2007;23(7):794.e1–794.e4. doi:10.1016/j.arthro.2006.09.007
- 60. Lykissas MG, Wall EJ, Nathan S.** Retro-articular drilling and bone grafting of juvenile knee osteochondritis dissecans: a technical description. *Knee Surg Sports Traumatol Arthrosc* 2014;22(2):274–278. doi:10.1007/s00167-013-2375-5
- 61. Masquijo JJ.** Localización preoperatoria mediante puntos de referencia radiográficos para facilitar las perforaciones retro-articulares en osteochondritis disecante juvenil (OCDJ): Nota técnica. Congreso SAOTI XXXVIII, Buenos Aires – Argentina, 2018.
- 62. Lee CK, Mercurio C.** Operative treatment of osteochondritis dissecans in situ by retrograde drilling and cancellous bone graft: a preliminary report. *Clin Orthop Relat Res* 1981;(158):129–126. doi:10.1097/00003086-198107000-00020
- 63. Bradley J, Dandy DJ.** Results of drilling osteochondritis dissecans before skeletal maturity. *J Bone Joint Surg [Br]* 1989;71(4):642–644. doi:10.1302/0301-620X.71B4.2768313
- 64. Aglietti P, Buzzi R, Bassi PB, Fioriti M.** Arthroscopic drilling in juvenile osteochondritis dissecans of the medial femoral condyle. *Arthroscopy* 1994;10(3):286–291. doi:10.1016/S0749-8063(05)80113-6
- 65. Anderson AF, Richards DB, Pagnani MJ, Hovis WD.** Antegrade drilling for osteochondritis dissecans of the knee. *Arthroscopy* 1997;13(3):319–324. doi:10.1016/S0749-8063(97)90028-1
- 66. Kocher MS, Micheli LJ, Yaniv M, et al.** Functional and radiographic outcome of juvenile osteochondritis dissecans of the knee treated with transarticular arthroscopic drilling. *Am J Sports Med* 2001;29(5):562–566. doi:10.1177/03635465010290050701
- 67. Louisia S, Beauflis P, Katabi M, Robert H; French Society of Arthroscopy.** Transchondral drilling for osteochondritis dissecans of the medial condyle of the knee. *Knee Surg Sports Traumatol Arthrosc* 2003;11(1):33–39. doi:10.1007/s00167-002-0320-0
- 68. Kawasaki K, Uchio Y, Adachi N, Iwasa J, Ochi M.** Drilling from the intercondylar area for treatment of osteochondritis dissecans of the knee joint. *Knee* 2003;10(3):257–263. doi:10.1016/S0968-0160(02)00104-7
- 69. Donaldson LD, Wojtys EM.** Extraarticular drilling for stable osteochondritis dissecans in the skeletally immature knee. *J Pediatr Orthop* 2008;28(8):831–835. doi:10.1097/BPO.0b013e31818ee248
- 70. Adachi N, Deie M, Nakamae A, et al.** Functional and radiographic outcome of stable juvenile osteochondritis dissecans of the knee treated with retroarticular drilling without bone grafting. *Arthroscopy* 2009;25(2):145–152.
- 71. Edmonds EW, Albright J, Bastrom T, Chambers HG.** Outcomes of extra-articular, intra-epiphyseal drilling for osteochondritis dissecans of the knee. *J Pediatr Orthop* 2010;30(8):870–878.
- 72. Hayan R, Phillipe G, Ludovic S, Claude K, Jean-Michel C.** Juvenile osteochondritis of femoral condyles: treatment with transchondral drilling. Analysis of 40 cases. *J Child Orthop* 2010;4(1):39–44. doi:10.1007/s11832-009-0225-2
- 73. Goebel S, Steinert A, Rucker A, Rudert M, Barthel T.** Minimally invasive retrograde drilling of osteochondral lesions of the femur using an arthroscopic drill guide. *Oper Orthop Traumatol* 2011;23(2):111–120. doi:10.1007/s00064-011-0014-1
- 74. Ojala R, Kerimaa P, Lakovaara M, et al.** MRI-guided percutaneous retrograde drilling of osteochondritis dissecans of the knee. *Skeletal Radiol* 2011;40(6):765–770. doi:10.1007/s00256-011-1118-2

- 75. Boughanem J, Riaz R, Patel RM, Sarwark JF.** Functional and radiographic outcomes of juvenile osteochondritis dissecans of the knee treated with extra-articular retrograde drilling. *Am J Sports Med* 2011;39(10):2212–2217. doi:10.1177/0363546511416594
- 76. Yonetani Y, Tanaka Y, Shiozaki Y, et al.** Transarticular drilling for stable juvenile osteochondritis dissecans of the medial femoral condyle. *Knee Surg Sports Traumatol Arthrosc* 2012;20(8):1528–1532. doi:10.1007/s00167-011-1736-1
- 77. Shaikh HH, Vícha J, Proček T, Pavlata J, Kučera T.** Osteochondritis dissecans of the knee in children and adolescents: our experience with transchondral drilling. *Acta Med (Hradec Kralove)* 2015;58(3):98–103. doi:10.14712/18059694.2015.101
- 78. Gunton MJ, Carey JL, Shaw CR, Murnaghan ML.** Drilling juvenile osteochondritis dissecans: retro- or transarticular? *Clin Orthop Relat Res* 2013;471(4):1144–1151. doi:10.1007/s11999-011-2237-8
- 79. Smillie IS.** Treatment of osteochondritis dissecans. *J Bone Joint Surg [Br]* 1957;39-B(2):248–260. doi:10.1302/0301-620X.39B2.248
- 80. Kivistö R, Pasanen L, Leppilähti J, Jalovaara P.** Arthroscopic repair of osteochondritis dissecans of the femoral condyles with metal staple fixation: a report of 28 cases. *Knee Surg Sports Traumatol Arthrosc* 2002;10(5):305–309. doi:10.1007/s00167-002-0294-y
- 81. Mackie IG, Pemberton DJ, Maheson M.** Arthroscopic use of the Herbert screw in osteochondritis dissecans. *J Bone Joint Surg [Br]* 1990;72(6):1076. doi:10.1302/0301-620X.72B6.2246293
- 82. Larsen MW, Pietrzak WS, DeLee JC.** Fixation of osteochondritis dissecans lesions using poly(L-lactic acid)/ poly(glycolic acid) copolymer bioabsorbable screws. *Am J Sports Med* 2005;33(1):68–76. doi:10.1177/0363546504265927
- 83. Kocher MS, Czarnecki JJ, Andersen JS, Micheli LJ.** Internal fixation of juvenile osteochondritis dissecans lesions of the knee. *Am J Sports Med* 2007;35(5):712–718. doi:10.1177/0363546506296608
- 84. Fridén T, Rydholm U.** Severe aseptic synovitis of the knee after biodegradable internal fixation. A case report. *Acta Orthop Scand* 1992;63(1):94–97. doi:10.3109/17453679209154859
- 85. Mainil-Varlet P, Rahn B, Gogolewski S.** Long-term in vivo degradation and bone reaction to various polylactides. 1. One-year results. *Biomaterials* 1997;18(3):257–266. doi:10.1016/S0142-9612(96)00126-3
- 86. Böstman OM.** Osteolytic changes accompanying degradation of absorbable fracture fixation implants. *J Bone Joint Surg [Br]* 1991;73(4):679–682. doi:10.1302/0301-620X.73B4.1649195
- 87. Tabaddor RR, Banffy MB, Andersen JS, et al.** Fixation of juvenile osteochondritis dissecans lesions of the knee using poly 96L/4D-lactide copolymer bioabsorbable implants. *J Pediatr Orthop* 2010;30(1):14–20. doi:10.1097/BPO.0b013e3181c6318c
- 88. Adachi N, Deie M, Nakamae A, et al.** Functional and radiographic outcomes of unstable juvenile osteochondritis dissecans of the knee treated with lesion fixation using bioabsorbable pins. *J Pediatr Orthop* 2015;35(1):82–88. doi:10.1097/BPO.0000000000000226
- 89. Berlet GC, Mascia A, Miniaci A.** Treatment of unstable osteochondritis dissecans lesions of the knee using autogenous osteochondral grafts (mosaicplasty). *Arthroscopy* 1999;15(3):312–316. doi:10.1016/S0749-8063(99)70041-1
- 90. Miura K, Ishibashi Y, Tsuda E, Sato H, Toh S.** Results of arthroscopic fixation of osteochondritis dissecans lesion of the knee with cylindrical autogenous osteochondral plugs. *Am J Sports Med* 2007;35(2):216–222. doi:10.1177/0363546506294360
- 91. Sasaki K, Matsumoto T, Matsushita T, et al.** Osteochondral autograft transplantation for juvenile osteochondritis dissecans of the knee: a series of twelve cases. *Int Orthop* 2012;36(11):2243–2248. doi:10.1007/s00264-012-1648-9
- 92. Lintz F, Pujol N, Pandeirada C, Boisrenoult P, Beaufile P.** Hybrid fixation: evaluation of a novel technique in adult osteochondritis dissecans of the knee. *Knee Surg Sports Traumatol Arthrosc* 2011;19(4):568–571. doi:10.1007/s00167-010-1259-1
- 93. Chadli L, Steltzlen C, Toanen C, et al.** Hybrid fixation in adult osteochondritis dissecans of the knee. *Orthop Traumatol Surg Res* 2018;104(2):223–225. doi:10.1016/j.otsr.2017.10.005
- 94. Polousky JD, Albright J.** Salvage techniques in osteochondritis dissecans. *Clin Sports Med* 2014;33(2):321–333. doi:10.1016/j.csm.2014.01.004
- 95. Steadman JR, Briggs KK, Rodrigo JJ, et al.** Outcomes of microfracture for traumatic chondral defects of the knee: average 11-year follow-up. *Arthroscopy* 2003;19(5):477–484. doi:10.1053/j.jars.2003.50112
- 96. Hangody L, Füles P.** Autologous osteochondral mosaicplasty for the treatment of full-thickness defects of weight-bearing joints: ten years of experimental and clinical experience. *J Bone Joint Surg [Am]* 2003;85-A(suppl 2):25–32. doi:10.2106/00004623-200300002-00004
- 97. Gudas R, Simonaityte R, Cekanaukas E, Tamosiūnas R.** A prospective, randomized clinical study of osteochondral autologous transplantation versus microfracture for the treatment of osteochondritis dissecans in the knee joint in children. *J Pediatr Orthop* 2009;29(7):741–748. doi:10.1097/BPO.0b013e3181b8f6c7
- 98. Heyworth BE, Kocher MS.** Osteochondritis dissecans of the knee. *JBS Rev* 2015;3(7):01874474-201503070-00003. doi:10.2106/JBS.RVW.N.00095
- 99. Minas T, Peterson L.** Advanced techniques in autologous chondrocyte transplantation. *Clin Sports Med* 1999;18(1):13–44, v–vi. doi:10.1016/S0278-5919(05)70128-9
- 100. Mithöfer K, Minas T, Peterson L, Yeon H, Micheli LJ.** Functional outcome of knee articular cartilage repair in adolescent athletes. *Am J Sports Med* 2005;33(8):1147–1153. doi:10.1177/0363546504274146
- 101. DiBartola AC, Wright BM, Magnussen RA, Flanigan DC.** Clinical outcomes after autologous chondrocyte implantation in adolescents' knees. A systematic review. *Arthroscopy* 2016;32(9):1905–1916. doi:10.1016/j.arthro.2016.03.007
- 102. Nepple JJ, Milewski MD, Shea KG.** Research in osteochondritis dissecans of the knee: 2016 update. *J Knee Surg* 2016;29(7):533–538. doi:10.1055/s-0036-1586723